

The Effectiveness of Triamcinolone Injection on Risk of Postoperative Operations with the Conjunctiva Autograft Technique and Its Association with Change of VEGF mRNA Expression

by Andi Muhammad Ichsan

Submission date: 20-Dec-2021 09:27AM (UTC+0700)

Submission ID: 1733932220

File name: edical_Pharmacology_Journal_Effectiveness_of_Triamcinolone_1.pdf (290.07K)

Word count: 3789

Character count: 20656

The Effectiveness of Triamcinolone Injection on Risk of Postoperative Operations with the Conjunctiva Autograft Technique and Its Association with Change of VEGF mRNA Expression

Purnamanita¹, Budu², Mochammad Hatta³, Muhammad Nasrum Massi³,
Rosdiana Natzir⁴, A. M. Ichsan² and Hidayat Sujuti⁵

¹Public Eye Health Centre Makassar, Indonesia.

²Department of Ophthalmology Faculty of Medicine Hasanuddin University Makassar, Indonesia.

³Molecular Biology and Immunology Laboratory, Faculty of Medicine, Hasanuddin University Makassar, Indonesia.

⁴Department of Biochemistry, Faculty of Medicine Hasanuddin University Makassar, Indonesia.

⁵Department of Ophthalmology, Faculty of Medicine Brawijaya University Malang, Indonesia.

*Corresponding Author E-mail : hattaram@yahoo.com

<http://dx.doi.org/10.13005/bpj/1916>

30

(Received: 12 March 2020; accepted: 09 April 2020)

To evaluate the effectiveness of 20 mg subconjunctival injections of Triamcinolone and their relationship to changes in VEGF mRNA expression on the risk of postoperative recurrence. Methods: Ten patients with stage II pterygium were divided into two groups, each group consisted of 5 samples given a subconjunctival injection of 20 mg Triamcinolone, and 5 samples given a placebo injection containing Balance Salt Solution (BSS), and venous blood was taken one week before excision. One week after injection, pterygium excision was performed using conjunctival autograft technique. One month postoperatively, VEGF mRNA expression was examined by taking venous blood and clinical changes after the injection was observed. Results: From 10 samples of pterygium patients, changes of expression in VEGF mRNA in the Triamcinolone group were 5.4 ± 0.96 and in the placebo group, the expression in VEGF mRNA was 1.27 ± 0.31 , $p = 0.006$. The expression of mRNA in pterygium tissue in the Triamcinolone group was 8.98 ± 1.04 and in the placebo group it was 7.75 ± 0.62 , $p = 0.07$. Clinical features appeared to be more minimal in the triamcinolone group than in the placebo group. Conclusion: The administration of subconjunctival injection of 20 mg Triamcinolone and the excision with conjunctival autograft is more effective in suppressing postoperative inflammation. It means that the likelihood of post-excision recurrence risk is smaller in this group compared to placebo.

Keywords: mRNA VEGF; Pterygium; Recurrence; Triamcinolone.

Pterygium is fibrovascular dysplasia in the triangular bulb conjunctiva, usually located in the nasal part of the conjunctiva¹. Growth of conjunctival tissue is triggered by inflammation due to chronic eye irritation. Generally, pterygium is

asymptomatic, but this can result in inflammation, invasive and tissue proliferation and postoperative recurrence². Pterygium can interfere the vision when it covers the pupil, but patients are usually operated on for cosmetic reasons³. Handling pterygium in



the form of surgery, several techniques are used such as bare sclera, autologous conjunctival graft or with amniotic membrane⁴.

Corticosteroids have long been used in ocular inflammation, which can be given in topical, subconjunctival, intraocular and systemic forms. Triamcinolone is one of the most commonly used corticosteroids, available in two forms, acetate and diacetate, which is an intermediate-acting corticosteroid that has a working period of up to 6 weeks when injected⁵. Triamcinolone acetate is the most widely used drug worldwide. Triamcinolone injection in the eye is available in suspension form, can be given periocularly or intraocularly. The administration of triamcinolone injection has been reported in cases of Anterior scleritis, Corneal graft rejection, Vernal keratoconjunctivitis, Uveitis, Episcleritis, Pterygium surgery, Superior limbic keratoconjunctivitis, Corneal graft, Herpetic keratitis, Intraocular surgery, Thyroid eye disease, and Neovascularization⁵.

The main therapy in pterygium is excision surgery, can be in the form of a simple excision (bare-sclera technique) or excision of the graft (conjunctival graft or amnion graft). Postoperative recurrence can occur. Recurrence of pterygium is characterized by proliferation and migration of fibroblasts. To prevent recurrence, fibrovascular activity as a sign of recurrence impending must be stopped immediately, one of which is by giving intralesional injection⁶. Triamcinolone is an intermediate-acting steroid that plays a role in decreasing fibroblast activity, formation of new blood vessels and inflammation. The technique of intralesional administration as an adjuvant therapy gives higher concentrations directly to the fibrovascular area, thereby providing a better inhibitory effect and lower recurrence compared to topical steroids⁷. Intralesional therapy does not only inhibit recurrence but also improves the appearance of areas that are exposed to. Conjunctival injection, thickening and size of fibrovascular tissue are generally smaller in the triamcinolone group.

Triamcinolone acetate inhibits angiogenesis directly through the influence of vascular endothelial cells and indirectly through other cells released by various cytokines that cause angiogenesis⁸. There are 2 types of corticosteroid injections; the short-acting type such as dexamethasone and long-acting type such as

triamcinolone and hydrocortisone. Triamcinolone is soluble in water and has an effect of 15-21 days. The use of subconjunctival corticosteroids in preventing recurrence has not been explored either⁹. VEGF is a key in the process of physiological angiogenesis during embryogenesis, bone growth and reproductive function, but also plays a role in the pathological angiogenesis process such as tumor growth, intraocular neovascular syndrome¹⁰. VEGF plays a role in diseases in the anterior segment, as in pterygium. Corneal neovascularization can lead to impaired visual acuity and determined caused by inflammation and corneal scarring¹¹. VEGF affects the increase in vascular permeability, angiogenesis and lymphangiogenesis, which causes an increase in VEGF expression, which causes neovascularization and inflammation in the pterygium¹². The purpose of this study was to assess how effective the administration of subconjunctival injection of 20 mg Triamcinolone to Vascular Endothelial Growth Factor (VEGF) mRNA expression, in blood and pterygium tissue in pterygium patients operated on by conjunctival autograft techniques.

MATERIAL AND METHODS

This research was conducted after obtaining approval from the ethics committee. Every subject included in the study was recorded for the identity and made no objections made to be included in this study (informed consent). In this study, all actions were taken with the consent of the subjects through an informed consent sheet, after the subjects received an explanation of the actions to be taken, and after the study was declared to meet ethical requirements to be carried out from the Ethics Commission on Human Health Research at the Faculty of Medicine, Hasanuddin University, RSUH and RSWS Makassar. Ten eyes out of ten people suffering from pterygium who met the inclusion criteria included in this study. The inclusion criteria included patients aged 30-45 years who were diagnosed with stage II primary pterygium according to Bharvaga criteria and did not suffer from systemic diseases which were contraindicated for excision such as not suffering from diabetes mellitus or hypertension. As for exclusionary criteria, ie suffering from pseudopterygium, suffering from an infectious

disease of the eye, pterygium excision had been performed before, had only one eye to see and which was not cooperative during sampling. Age and sex of each study subject were recorded, visual acuity in both eyes was examined, slit lamp examination was performed to determine the type of pterygium and its degree / stage, as well as examination of eyeball pressure, blood pressure examination and random blood sugar (RBS) examination was performed and all examination results above were recorded.

In this study, venous blood of all patients was taken for examination of Vascular Endothelial Growth Factor (VEGF) mRNA expression before injection. Then, the patients were divided into 2 groups, 5 people received subconjunctival injection of 20 mg Triamcinolone acetate (Flamcort 40 mg, vial @1 ml), and 5 people received subconjunctival injection of Balanced Salt Solution. Everything that happened as a result of the injection was recorded. All actions were carried out under an operating microscope. One week after injection, pterygium excision surgery was performed. The surgical procedure was carried out under an operating microscope. After speculum placement, anesthesia was performed by subconjunctival injection of 2% Lidocain. The pterygium head was released from the cornea by using a knife. The fibrovascular tissue that lies beneath the conjunctiva was carefully removed and cut with tenotomy scissors. The sclera and cornea were cleaned from the remaining pterygium using a curette. Autolimb conjunctival graft was performed with a size corresponding to the excised tissue. At the end of the surgery, antibiotic and dexamethasone eye ointment (Cendo

Xitrol) were given. Post surgery, antibiotic and steroid eye drops (Cendo Xitrol) and lubricant eye drops (Cendo Lyteers) were given. Samples of the pterygium that had been taken were then placed in transport media and stored in an ice box to be taken to the laboratory and stored in the -20°C for real-time PCR examination. The excised tissue was checked for Vascular Endothelial Growth Factor (VEGF) mRNA expression levels.

Postoperative evaluation on day 1, week 1, and one month after surgery is done while assessing signs of postoperative recurrence. One month after excision another venous blood was taken to assess the Vascular Endothelial Growth Factor (VEGF) levels. Examination of mRNA of VEGF gene in blood and pterygium tissue by real-time PCR according to previous study done by first extracting nucleic acid, then RNA amplification is done using the primers VEGF for: 5'-GCA CCC ATG GCA GAA GG-3' and VEGF Rev: 5'-CTC GAT TGG ATG GCA GTA T-3', while Housekeeping gene are β-actin for: 2'-CGC CCA GCA CGA TGA AA-3' β-actin rev: 5'-CCG CCG ATC CAC ACA GA-3'. The target gene mRNA expression profile was determined and after that the calibration curve with cycle threshold (Ct) was calculated and the relative quantization of target gene expression was evaluated using the Ct comparison method^{12,13}. All data obtained were grouped according to the purpose and type of data. Univariate analysis was carried out on each of the variables studied to determine the description of the frequency distribution and data normality of all research variables. Bivariate analysis was performed to determine the relationship between

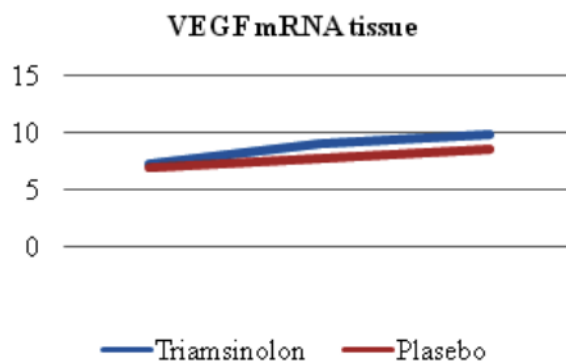


Fig. 1. Changes in VEGF mRNA expression in tissues

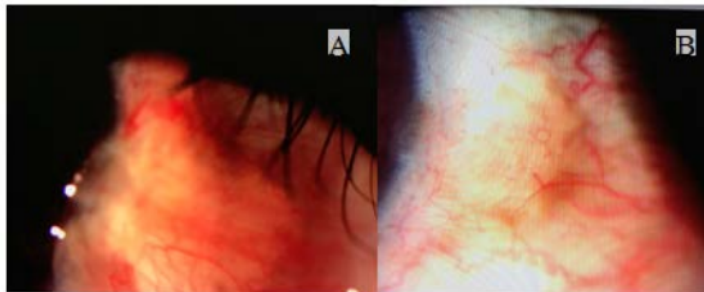
tables, if the normal data distribution used the Independent Sample T Test and Paired T test, whereas if the data distribution was not normal using the Wilcoxon test and multivariate analysis, using the Anova test. Statistical analysis using the IBM SPSS program version 23.0 with a degree of confidence of 95% and a value of $\alpha = 0.05$,

RESULTS AND DISCUSSIONS

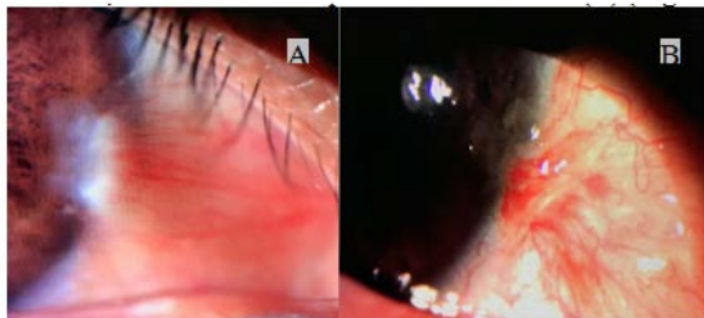
From the 10 samples studied, it was found that the age of the sample was 31-45 years, there were 7 women and 3 men, had lower secondary education, as many as those who worked and those who did not work. The change in VEGF mRNA expression between the Triamcinolone and placebo groups can be seen in Table 1.

Table 1. Comparison of changes in VEGF mRNA expression between the Triamcinolone and placebo groups

VEGF mRNA expression	N	Mean	Std. Deviation	Std. Error	95% Confidence Interval for Mean		Minimum	Maximum
					Lower Bound	Upper Bound		
Triamcinolone (blood)	5	3.9444	0.96316	0.43074	2.7484	5.1403	2.87	4.81
Placebo (blood)	5	1.27	0.31061	0.13891	0.8843	1.6557	0.96	1.76
Triamcinolone (tissue)	5	8.9874	1.04367	0.46674	7.6915	10.2833	7.3	9.83
Placebo (tissue)	5	7.7555	0.6259	0.27991	6.9783	8.5326	6.91	8.56



Changes in clinical features after injection of Triamcinolone (A), and postoperative month 1, Triamcinolone deposit was still visible (B) (Figure 2)



Changes in clinical features after placebo injection (A), and postoperative month 1, the conjunctiva was still hyperemic and signs of inflammation were still present (B) (Figure 3)

Fig. 2 & 3. Clinical changes after triamcinolone and placebo injection

In Table 1, changes in VEGF mRNA expression¹² in blood samples showed significant results in the Triamcinolone group, where VEGF mRNA expression was higher than in the placebo group, which was 3.94 ± 0.96 vs 1.27 ± 0.31 , $p = 0.006$. As for tissue samples, VEGF mRNA expression in the Triamcinolone group was also higher⁷ than in the placebo group, which was 8.98 ± 1.04 in the Triamcinolone group, and in the placebo group 7.75 ± 0.62 , $p = 0.07$ (Figure 1)

The clinical picture after injection in the Triamcinolone and placebo groups can be seen in the following figure (Figures 2 and 3).

DISCUSSION

From the³ research that had been done, the result was higher in expression in the Triamcinolone group compared to the placebo group and was statistically significant in blood samples, whereas in tissue samples the results obtained were not significant. The placebo group seems higher than in Triamcinolone group due to baseline sample, but mRNA VEGF expression decrease more higher than in placebo group one month after injection. In this study, significant results were obtained in the group given the injection of Triamcinolone, 3.94 ± 0.96 vs 1.27 ± 0.31 , $p = 0.006$. Triamcinolone reduced inflammation and therefore angiogenesis and neovascularization due inhibit to inflammation and VEGF not release from their receptor. This result was accordance with that obtained by Tong, 2006, who found that Triamcinolone inhibits the effect of angiogenesis by reducing VEGF from VEGF receptors. VEGF plays a role in the pathological angiogenesis process such as tumor growth, intraocular neovascular syndrome such as in pterygium¹⁰. VEGF affects the increase in vascular permeability, angiogenesis and lymphangiogenesis, which causes an increase in VEGF expression, which causes neovascularization and inf¹⁹ mation in the pterygium^{14,15}. VEGFR expression was significantly higher in pterygium than in the conjunctiva, high expression in pterygium compared to normal control and was associated with cell p³ liferation and angiogenesis in pterygium. VEGF plays a role in the formation of pterygium and contributes to the ability of pterygium angiogenesis. In addition, it was also found that the therapeutic response

to antiangiogenesis drugs might³ depend on the variant type of VEGF allele¹⁶. Tong *et al.* found that triamcinolone reduced VEGF mRNA expression in RPE cells in choroidal neovascularization and macular edema cases. It is suspected that triamcinolone inhibits the effects of angiogenesis from VEGF receptors by suppressing the production of VEGF or triamcinolone strengthens the expression of PEDF which is a potent inhibitor of angiogenesis¹⁷.

In this study, triamcinolone injection was only given once, one week before excision, and the expression of VEGF mRNA in the blood was lower than expression in pterygium tissue. Inflammatory process occurs in pterygium tissue and the injection will increase the inflammatory process that already exist, so, mRNA VEGF expression in tissue sample was higher than in the blood. A¹ study by Kang *et al.* found that triamcinolone was not potent as an anti-VEGF therapy in preventing neovascularization of the cornea. The inhibitory effect¹¹ is obtained if used together with Bevacizumab. The efficacy of steroids¹¹ suppressing VEGF expression was lower than the direct mechanism of anti-VEGF, hence the combination of triamcinolone and bevacizumab makes a¹ greater inhibitory effect than single anti VEGF. VEGF itself plays a major role in angiogenesis while steroids have a smaller role. However, the combination of triamcinolone and bevacizumab did not provide significant results compared to bevacizumab therapy alone in the management of corneal neovascularization¹⁸. VEGF mRNA can be analyzed by RT-PCR, realtime PCR, Elisa and Western blots. Sava *et al.* obtained 40% of pterygium samples having high mRNA amplification¹⁹. High levels of VEGF mRNA detected in basal cells could be explained²¹ phenotypes and specific behaviors as explained by Chui *et al.* which says that basal cells have premalignant features²⁰. In the clinical picture 1 month after injection as shown in Tables 2 and 3, it appeared that the conjunctiva was still hyperemic in the placebo group, whereas in the Triamcinolone group there was a picture of hyperemia limited by triamcinolone deposits. Athanasiadis states that the injection of local Triamcinolone²⁶ suppressed the immune response for some time, due to the natural crystalline nature of this drug⁵. The presence of this substance for several months in the body locally makes this drug classified as

intermediate glucocorticoids, its strength is 4x stronger than hydrocortisone and 5x stronger than betamethasone²¹. Parenterally, the biological half-life of triamcinolone is 18-36 hours²². Kalina, 1995 reported that triamcinolone deposits can last up to 13 months after injection²³.

Also, Prabhasawat (2006) reported that pterygium fibrovascular tissue had not developed optimally until 6 months postoperatively, so that if given before perfect proliferation occurs, it would give better results, reducing the use of excessive drugs that risked increased complications. Intralesional injection of 5 FU with triamcinolone was more effective in preventing impending recurrence compared with only topical steroids⁶. The most efficient subconjunctival injection of Triamcinolone was given by the technique of making white crystal precipitation and removing the supernatant before injection, this could be done if placing the insulin with upright position and taking into account the crystal separation from the solvent. If 1 ml of triamcinolone is given, a precipitate of 0.1 – 0.15 ml will be obtained. The presence of white areas at the time of injection in the subconjunctiva showed the formation of the drug deposits, so that absorption through the cornea can be longer and the risk of side effects from preservatives can be minimized^{5,24}. The weakness of this study is that the subjects studied were small in number, that was, only 10 eyes, no data on pterygium tissue before surgery due to ethical factors, and only postoperative tissue was analyzed, so there was no comparison between expression before and after tissue injection. In addition, follow-up and examination of VEGF mRNA expression was not long enough; only take up to 1 month after injection, so that the risk of recurrence cannot be further analyzed, although it can be expected that the greatest risk of recurrence is in the placebo group.

CONCLUSION

Expression of mRNA VEGF decreased after the administration of subconjunctival injection of 20mg Triamcinolone with conjunctival autograft effective in suppressing postoperative inflammation.

ACKNOWLEDGEMENT

Thanks to all registered patients at Public Eye Health Centre Makassar, Indonesia who participated in the study.

REFERENCES

1. Nangia V, Jonas JB, Nair D, Saini N, Nangia P, Panda-Jonas S. Prevalence and associated factors for pterygium in rural agrarian Central India. The Central India Eye and Medical Study. *PLoS One.*; **8**(12):1–6 (2013).
2. Theman HCI, Mans DRA, Bipat R, Doelwijt DJ, Jiawan D, de Mesquita-Voigt ATB. Possible correlation of plica-limbal distance with the presence of primary medial pterygium. *Transl Biomed.*; **1**(2) (2010).
3. Fotouhi A, Hashemi H, Khabazkhoob M, Mohammad K. Prevalence and risk factors of pterygium and pinguecula: The Tehran Eye Study. *Eye.*; **23**(5):1125–9 (2009).
4. Alpay A, Uçurba° SH, Erdoçan B. Comparing techniques for pterygium surgery. *Clin Ophthalmol.*; **3**(1):69–74 (2009).
5. Athanasiadis Y, Tsatsos M, Sharma A, Hossain P. Subconjunctival triamcinolone acetonide in the management of ocular inflammatory disease. *J Ocul Pharmacol Ther.*; **29**(6):516–22 (2013).
6. Prabhasawat P, Tesavibul N, Leelapatranura K, Phonjan T. Efficacy of Subconjunctival 5-Fluorouracil and Triamcinolone Injection in Impending Recurrent Pterygium. *Ophthalmology.*; **113**(7):1102–9 (2006).
7. Hill JC. Pathogenesis of pterygium. *Eye.*; **3**(2):218–26 (1989).
8. Murata M, Shimizu S, Horiuchi S, Taira M. Inhibitory effect of triamcinolone acetonide on corneal neovascularization. *Graefes Arch Clin Exp Ophthalmol.*; **244**(2):205–9 (2006).
9. Singh S, Pal V, Dhull C. Supratarsal injection of corticosteroids in the treatment of refractory vernal keratoconjunctivitis. *Indian J Ophthalmol.*; **49**(4):241–5 (2001).
10. Ferrara N, Gerber HP, LeCouter J. The biology of VEGF and its receptors. *Nat Med.*; **9**(6):669–76 (2003).
11. Comel S, Adriana ID, Mihaela TC, Speranta S, Algerino DS, Mehdi B, *et al.* Anti-vascular endothelial growth factor indications in ocular disease. *Rom J Ophthalmol.*; **59**(4):235–42 (2015).
12. Ang Yuan, Chong-Jen Yu, Kwen-Tay Luh, Wen-Jone Chen, Fang-Yue Lin, Sow-Hsong Kuo,

- and Pan-Chyr Yang. Quantification of VEGF mRNA Expression in Non-Small Cell Lung Cancer Using a Real-Time Quantitative Reverse Transcription-PCR Assay and a Comparison with Quantitative Competitive Reverse Transcription-PCR. *Laboratory Investigation*. **80**(11):1671-1680 (2000).
13. Hatta M, Surachmanto EE, Islam AA, Wahid S. Expression of mRNA IL-17F and sIL-17F in atopic asthma patients. *BMC Research Notes*. **10**: 202 (2017). DOI: 10.1186/s13104-017-2517-9
 14. Zhou WP, Zhu YF, Zhang B, Qiu WY, Yao YF. The role of ultraviolet radiation in the pathogenesis of pterygia (Review). *Mol Med Rep.*; **14**(1):3–15 (2016).
 15. Witmer AN, Vrensen GFJM, Van Noorden CJF, Schlingemann RO. Vascular endothelial growth factors and angiogenesis in eye disease. *Progress in Retinal and Eye Research*. (2003).
 16. Peng ML, Tsai YY, Tung JN, Chiang CC, Huang YC, Lee H, *et al.* Vascular endothelial growth factor gene polymorphism and protein expression in the pathogenesis of pterygium. *Br J Ophthalmol.*; **98**(4):556–61 (2014).
 17. Tong JP, Lam DSC, Chan WM, Choy KW, Chan KP, Pang CP. Effects of triamcinolone on the expression of VEGF and PEDF in human retinal pigment epithelial and human umbilical vein endothelial cells. *Mol Vis.*; **12**(September 2005):1490–5 (2006).
 18. Kang S, Chung SK. The effect of subconjunctival combined treatment of bevacizumab and triamcinolone acetonide on corneal neovascularization in rabbits. *Cornea.*; **29**(2):192–6 (2010).
 19. Sava MGP, Raica ML, Cimpean AMG. VEGF mRNA assessment in human pterygium: A new “scope” for a future hope. *Ophthalmic Res.*; **52**(3):130–5 (2014).
 20. Chui J, Coroneo MT, Tat LT, Crouch R, Wakefield D, Di Girolamo N. Ophthalmic pterygium: A stem cell disorder with premalignant features. *Am J Pathol.*; **178**(2):817–27 (2011).
 21. Gaudio PA. A review of evidence guiding the use of corticosteroids in the treatment of intraocular inflammation. *Ocul Immunol Inflamm.*; **12**(3):169–92 (2004).
 22. Cárdenas-Cantú E, Zavala J, Valenzuela J, Valdez-García JE. Molecular Basis of Pterygium Development. *Semin Ophthalmol.*; **31**(6):567–83 (2016).
 23. Kalina PH, Erie JC, Rosenbaum L. Biochemical Quantification of Triamcinolone in Subconjunctival Depots. *J Chem Inf Model.*; **53**(9):1689–99 (2013).
 24. Ober MD, Barile GR, Tari SR, Tossi GM, Schiff WM, Chang S. Measurement of the Actual Dose of Triamcinolone Acetonide Delivered by Common Techniques of Intravitreal Injection. *Am J Ophthalmol.*; **142**(4):0–4 (2006).

The Effectiveness of Triamcinolone Injection on Risk of Postoperative Operations with the Conjunctiva Autograft Technique and Its Association with Change of VEGF mRNA Expression

ORIGINALITY REPORT

17%

SIMILARITY INDEX

8%

INTERNET SOURCES

13%

PUBLICATIONS

3%

STUDENT PAPERS

PRIMARY SOURCES

- 1 Seungbum Kang. "The Effect of Subconjunctival Combined Treatment of Bevacizumab and Triamcinolone Acetonide on Corneal Neovascularization in Rabbits :", Cornea, 02/2010
Publication 2%
- 2 www.nature.com
Internet Source 2%
- 3 www.ncbi.nlm.nih.gov
Internet Source 1%
- 4 biotech-asia.org
Internet Source 1%
- 5 M. Motokawa, M. Kaku, Y. Tohma, T. Kawata et al. "Effects of Cyclic Tensile Forces on the Expression of Vascular Endothelial Growth Factor (VEGF) and Macrophage-colony-stimulating Factor (M-CSF) in Murine 1%

Osteoblastic MC3T3-E1 Cells", Journal of Dental Research, 2016

Publication

6

Fabiana dos Santos Paris, Charles Costa de Farias, Gustavo Barreto Melo, Myrna Serapião dos Santos et al. "Postoperative Subconjunctival Corticosteroid Injection to Prevent Pterygium Recurrence", Cornea, 2008

Publication

1 %

7

"Oral Presentation - Critical Care Medicine", Respirology, 2014

Publication

1 %

8

Mendy Hatibie Oley, Maximillian Christian Oley, Albertus Djarot Noersasongko, Mochammad Hatta et al. "Effects of hyperbaric oxygen therapy on vascular endothelial growth factor protein and mRNA in crush injury patients: A randomized controlled trial study", International Journal of Surgery Open, 2021

Publication

1 %

9

"Poster Abstracts", Psychiatry and Clinical Neurosciences, 4/2006

Publication

1 %

10

Thomas Tommy, Andi A. Islam, Mochammad Hatta, Agussalim Bukhari, Nasrullah, Willy Adhimarta, Aminuddin, Andi Alfian Zainuddin. "Effect of folic acid on serum homocysteine,

1 %

TNF α , IL-10, and HMGB1 gene expression in head injury model", Annals of Medicine and Surgery, 2021

Publication

11

123docz.net

Internet Source

1 %

12

Choi, E.-K., S.-W. Kim, E.-J. Nam, J. Paek, G.-W. Yim, M.-H. Kang, and Y.-T. Kim. "Differential Effect of Intraperitoneal Albendazole and Paclitaxel on Ascites Formation and Expression of Vascular Endothelial Growth Factor in Ovarian Cancer Cell-Bearing Athymic Nude Mice", Reproductive Sciences, 2011.

Publication

1 %

13

Submitted to Jacksonville State University

Student Paper

1 %

14

Resiana Karnina, Syafri Kamsul Arif, Mochammad Hatta, Agussalim Bukhari et al. "Systemic lidocaine administration influences NF- κ B gene expression, NF- κ B and TNF- α protein levels on BALB/c mice with musculoskeletal injury", Annals of Medicine and Surgery, 2021

Publication

1 %

15

Submitted to Queen Mary and Westfield College

Student Paper

<1 %

16	Submitted to Universitas Airlangga Student Paper	<1 %
17	doaj.org Internet Source	<1 %
18	www.transbiomedicine.com Internet Source	<1 %
19	Junichi Fukuhara, Satoru Kase, Tsutomu Ohashi, Ryo Ando et al. "Expression of vascular endothelial growth factor C in human pterygium", Histochemistry and Cell Biology, 2012 Publication	<1 %
20	Nurul Fadilah Ali Polanunu, Sitti Wahyuni, Firdaus Hamid. " Seroprevalence and associated risk factors of infections among pregnant women in Makassar, Indonesia ", Cold Spring Harbor Laboratory, 2021 Publication	<1 %
21	www.karger.com Internet Source	<1 %
22	www.minervamedica.it Internet Source	<1 %
23	Mohammad Reza Fallah Tafti, Keivan Khosravifard, Mehrdad Mohammadpour, Mohammad Naser Hashemian, Mohammad Yaser Kiarudi. "Efficacy of Intralesional	<1 %

Bevacizumab Injection in Decreasing Pterygium Size", Cornea, 2011

Publication

24

Mohammad Reza Fallah, Keivan Khosravi, Mohammad Nasser Hashemian, Amir Hoshang Beheshtnezhad et al. "Efficacy of Topical Bevacizumab for Inhibiting Growth of Impending Recurrent Pterygium", Current Eye Research, 2009

Publication

25

Ning Zhou, Guangyuan Hu), Qi Mei, Hong Qiu, Guoxian Long, Chunli Chen, Hu Guoqing. "Inhibitory effect of endostar in combination with radiotherapy in a mouse model of human CNE2 nasopharyngeal carcinoma", Journal of Huazhong University of Science and Technology [Medical Sciences], 2011

Publication

26

Y Athanasiadis, D de Wit, V Kumar, John E Moore, Anant Sharma. "Reply to: Costa DC et al", Eye, 2008

Publication

27

Yi-Ryeong Park, Sung Kun Chung. "Inhibitory Effect of Topical Aflibercept on Corneal Neovascularization in Rabbits", Cornea, 2015

Publication

28

assets.cureus.com

Internet Source

<1 %

<1 %

<1 %

<1 %

<1 %

29 eprints.nottingham.ac.uk Internet Source <1 %

30 ijero.org Internet Source <1 %

31 www.wjgnet.com Internet Source <1 %

32 Ang Yuan, Chong-Jen Yu, Wen-Jone Chen, Fang-Yue Lin, Sow-Hsong Kuo, Kwen-Tay Luh, Pan-Chyr Yang. "Correlation of total VEGF mRNA and protein expression with histologic type, tumor angiogenesis, patient survival and timing of relapse in non-small-cell lung cancer", International Journal of Cancer, 2000
Publication

33 Hendriati. "The association of Cyp1A1 gene polymorphisms with Cyp1A1 enzymes, p53 protein, and vascular endothelial growth factor levels in pterygium", IOP Conference Series: Earth and Environmental Science, 2019
Publication

Exclude quotes On

Exclude matches < 5 words

Exclude bibliography On